



|   |   |
|---|---|
|   | <b>PRESENTING CLINICAL SIGNS</b>  |
| <b>DATE</b>                                     | History: Grade II-III/VI left-sided murmur. BP WNL.   |
| <b>3/7/22</b>                                   | <b>ECHOCARDIOGRAPHIC FINDINGS</b>   |
|   | 2D, M-mode, and Doppler study.  |
| <b>PERFORMED BY</b>                             | There is mild left atrial dilation. The mitral valve leaflets are thickened, and exhibit systolic prolapse. A mild to moderate jet of eccentric mitral regurgitation is present. There is mild left ventricular dilation. Left ventricular systolic function is hyperdynamic. The aorta and aortic valve are normal. Right atrial and right ventricular dimensions are normal. The tricuspid valve leaflets are mildly thickened, and a mild jet of tricuspid regurgitation is present. TR velocity does not suggest the presence of pulmonary hypertension. The pulmonary artery and pulmonic valve are normal. No shunting lesions are visualized. No pericardial effusion or cardiac masses are seen.  |
| Sara Hansen                                     |   |
| <b>INTERPRETED BY</b>                           |   |
| Keith Blass, DVM,<br>MS, DACVIM<br>(Cardiology) | LA - 31.7 mm<br>LVIDd - 31.5 mm<br>LVIDs - 16.3 mm<br>FS - 48%<br>RA - 11.7 mm<br>LVOT - 1.47 m/s<br>RVOT - 1.10 m/s<br>TR - 2.31 m/s   |
| <b>PATIENT</b>                                  |   |
| Apollo McCullen                                 |   |
| <b>SPECIES</b>                                  | <b>ELECTROCARDIOGRAPHIC FINDINGS</b>  |
| Canine  | A single lead ECG is submitted for review.  |
|   | HR: 128 bpm<br>Rhythm: Sinus  |
| <b>BREED</b>                                    |   |
| Min. Poodle                                     | Normal sinus rhythm is present throughout this recording. All complex amplitudes and intervals are within normal limits. No premature beats or conduction blocks are seen.  |
|   | <b>ASSESSMENT/RECOMMENDATIONS</b>   |
| <b>SEX</b>                                      | Degenerative mitral and tricuspid valve disease   |
| <b>MN</b>                                       | This examination demonstrates regurgitation of blood across Apollo's mitral and tricuspid valves resulting from degenerative valve disease. Apollo's tricuspid valve disease is mild, and appears to be well-compensated. His mitral valve disease is a bit more advanced, as Apollo has mild to moderate mitral regurgitation present, with mild secondary dilation of both his left atrium and left ventricle, though his left ventricular systolic function is well-preserved. As only mild left heart chamber dilation is present, Apollo's current risk for the development of clinical signs, such as coughing, exercise intolerance, syncope, and labored breathing, appears to be relatively low, though careful monitoring for these signs is recommended. |
| <b>AGE</b>                                      |   |
| 10 y  |   |
| <b>WEIGHT</b>                                   | I recommend starting Apollo on pimboendan (2.5 mg am, 1.25 mg pm), as this medication should help to slow the progression of his mitral valve disease.  |
| 14.8 lb   |   |
| <b>HOSPITAL NAME</b>                            | A recheck echocardiogram is recommended in 6-9 months. Thoracic radiographs are recommended if Apollo experiences respiratory clinical signs.   |
| H & H Veterinary<br>Care                        |   |
| <b>REFERRING VET</b>                            |   |
| Dr. Henery                                      |   |



DATE

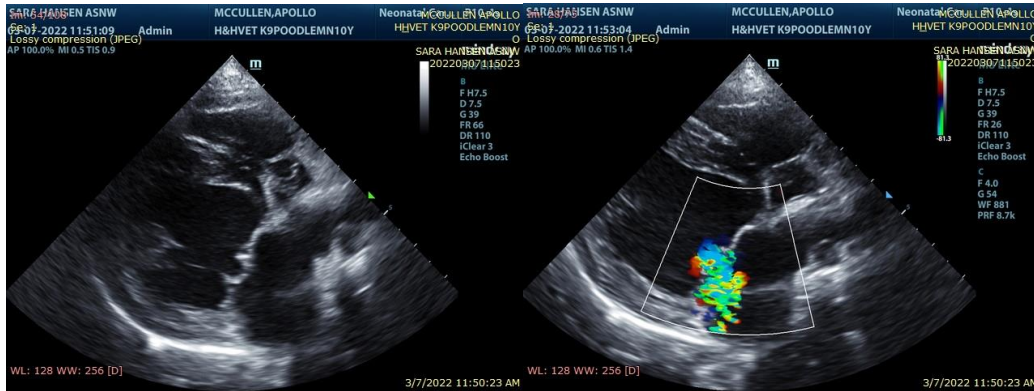
3/7/22

PERFORMED BY

Sara Hansen

INTERPRETED BY

Keith Blass, DVM,  
MS, DACVIM  
(Cardiology)



The information and recommendations provided are based on the images presented by the referring veterinarian. No evaluation can be communicated regarding pathology that was not visible in the image/video clips provided.

PATIENT

Apollo McCullen

Thank you for this referral. If the clinical or image interpretation does not parallel your findings or if I can be of any further assistance please contact me.

Keith Blass, DVM, MS, DACVIM (Cardiology)  
KeithBlass@gmail.com  
631-804-5754

SPECIES

Canine

BREED

Min. Poodle

SEX

MN

AGE

10 y

WEIGHT

14.8 lb

HOSPITAL NAME

H & H Veterinary  
Care

REFERRING VET

Dr. Henery